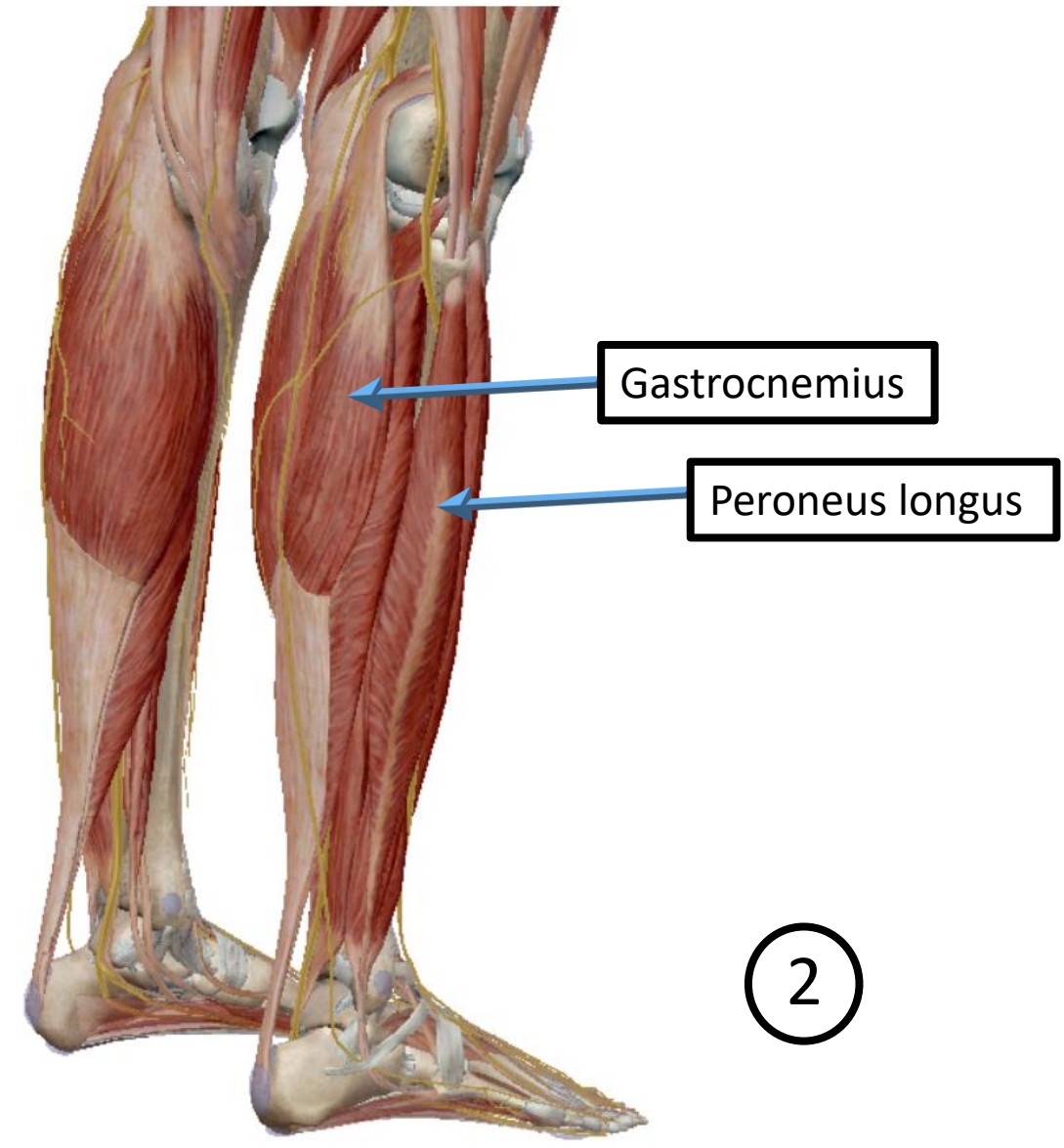
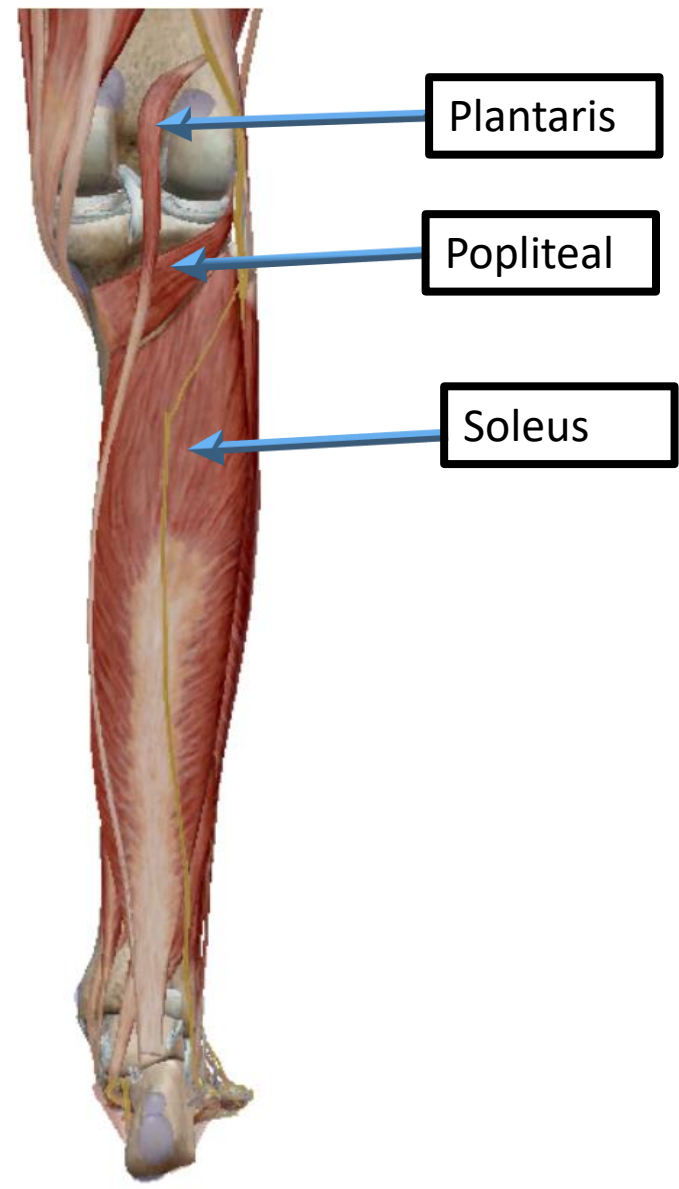


Posterior Muscle Review

Brian John Piccolo, MA, LMT

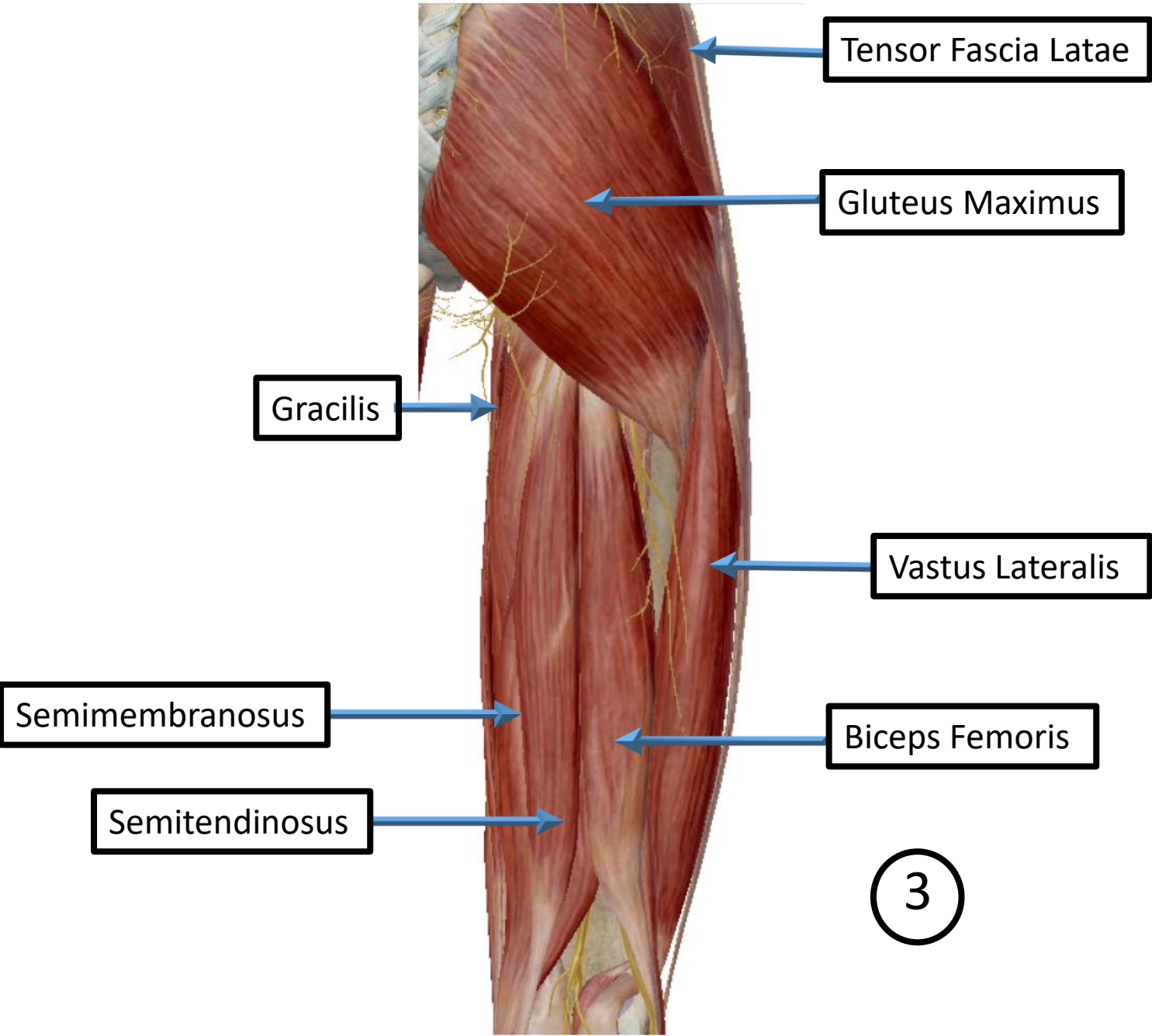
Lower Leg

1

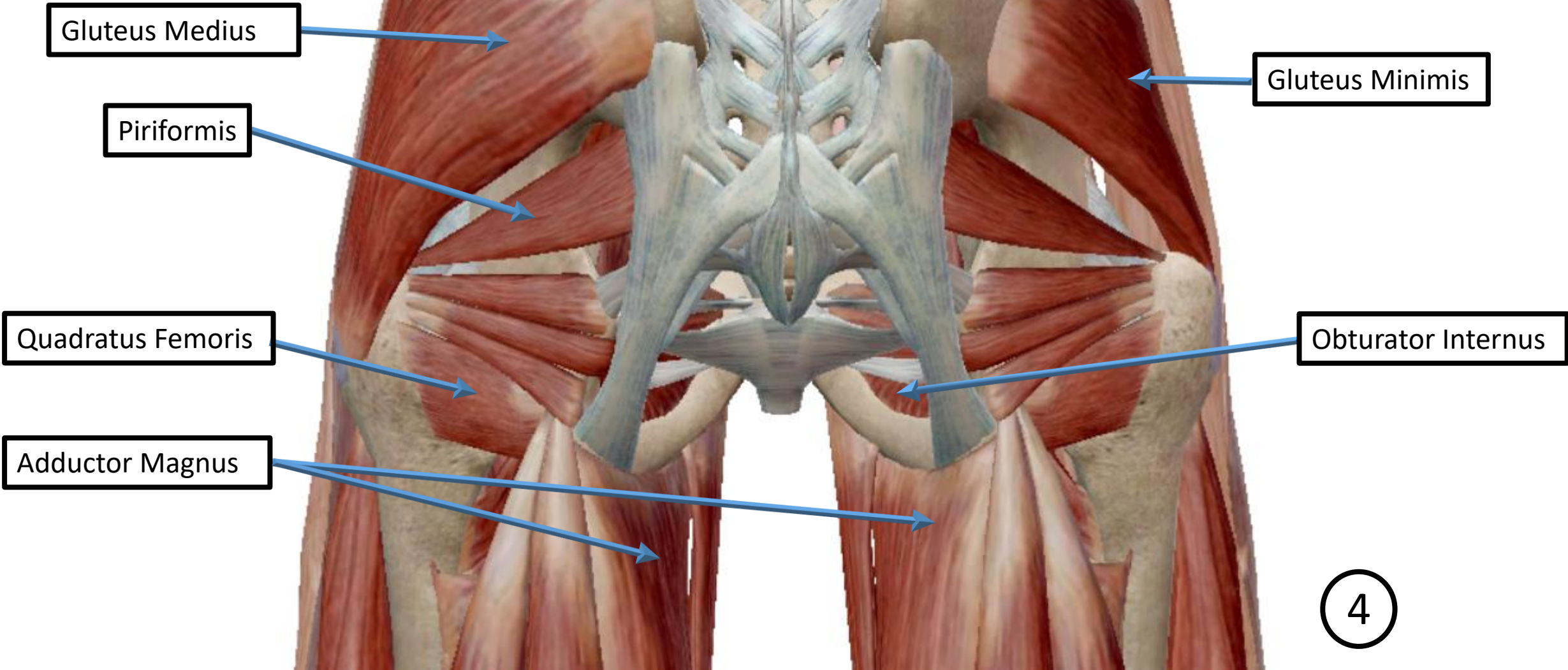


2

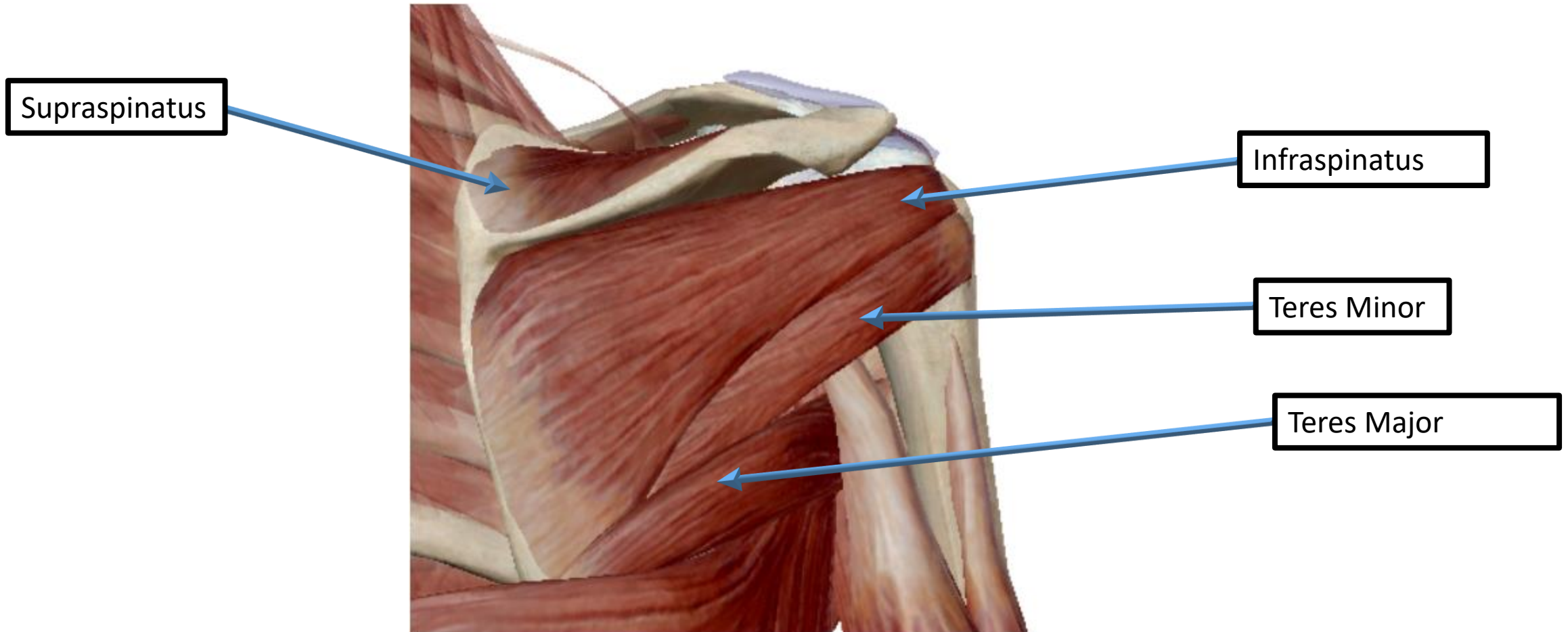
Upper Leg-Hip

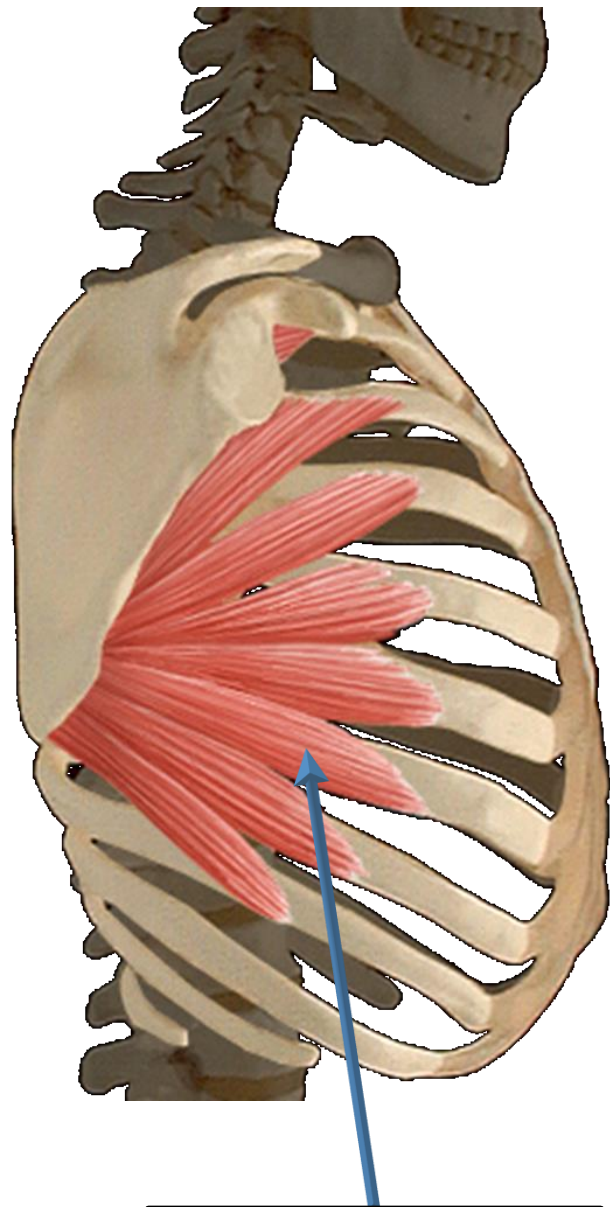


Gluteal Hip



Shoulder



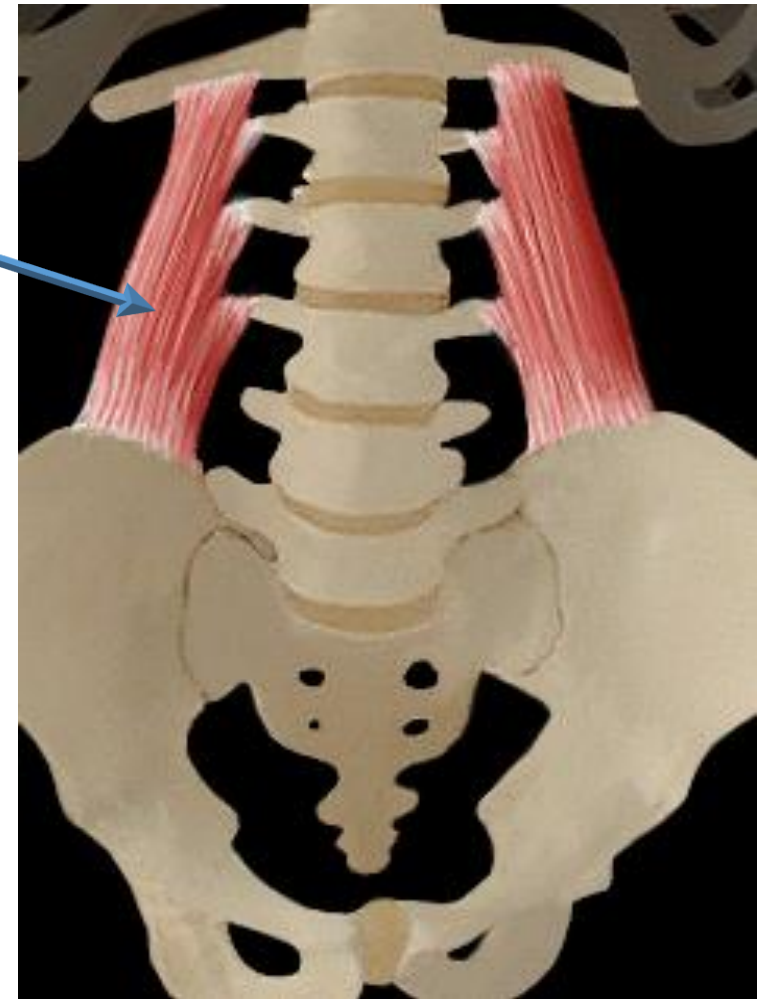


Serratus Anterior

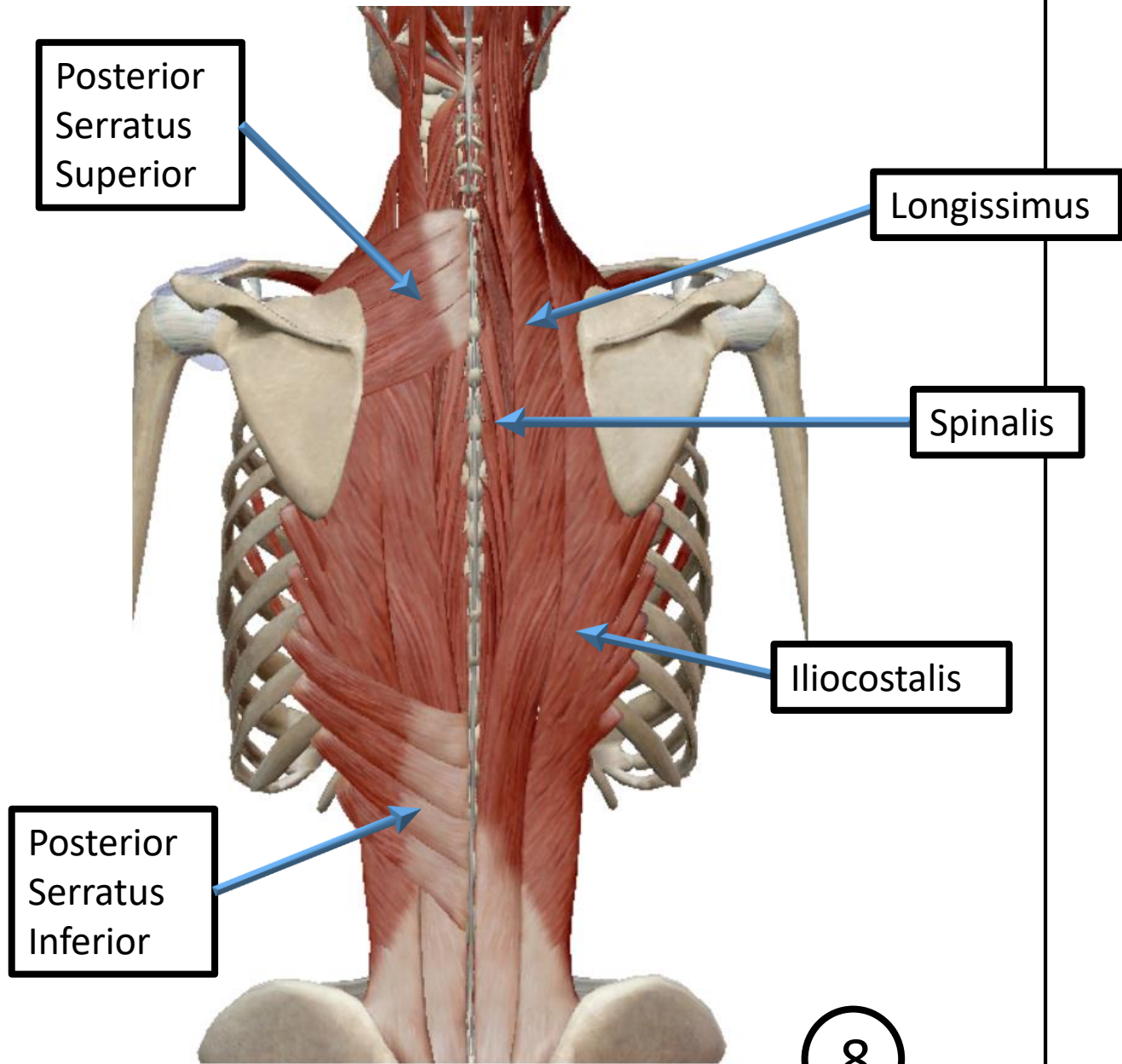
6

Trunk

Quadratus Lumborum

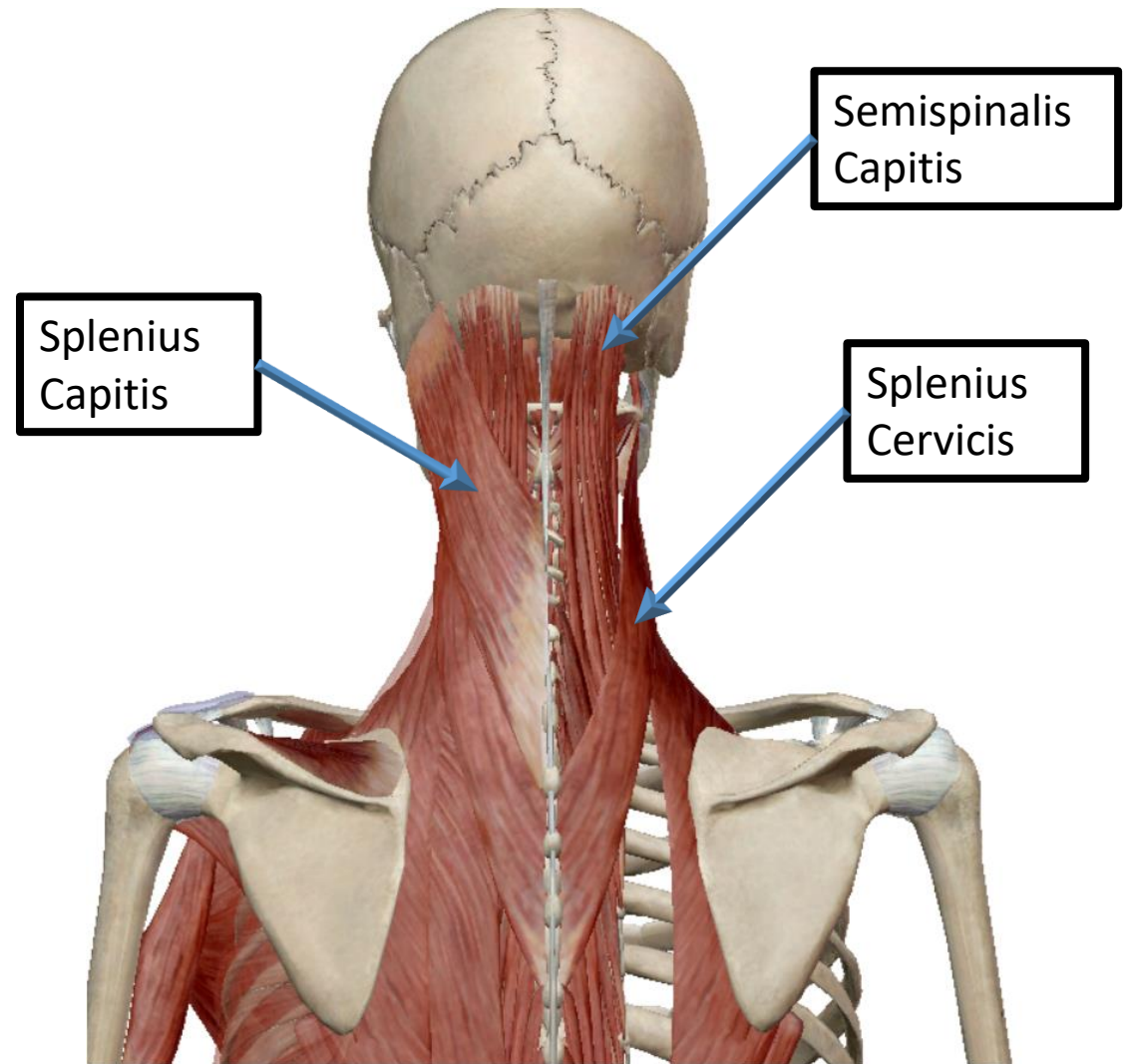


7



9

Trunk-Neck



Trunk-Neck

