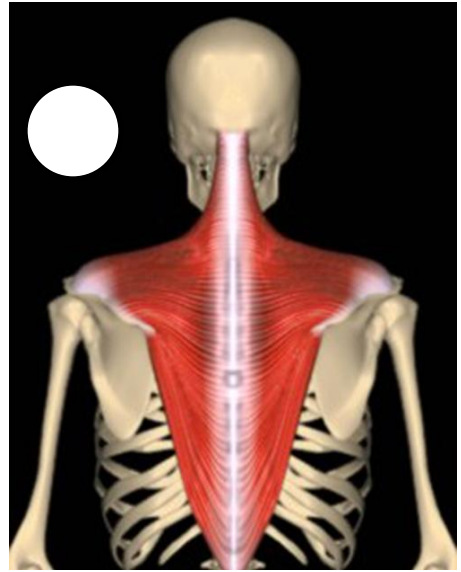
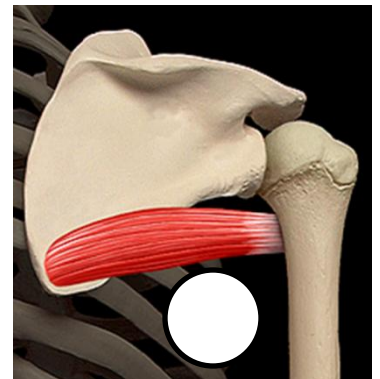
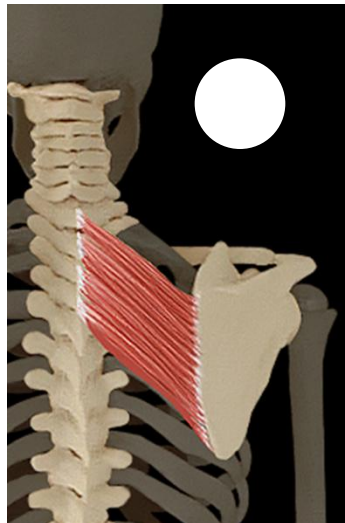
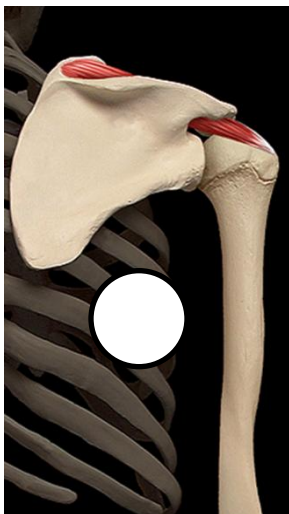
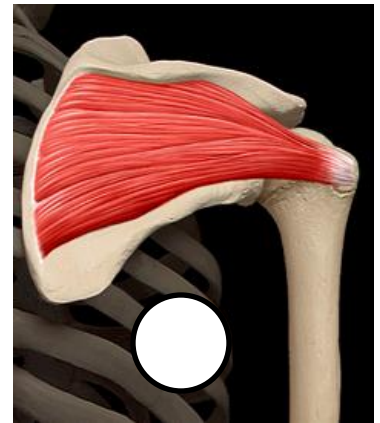


# Posterior Origin and Insertion Exam



- (A) **O:** Infraspinous fossa of scapula.  
**I:** Greater tubercle of humerus.
- (B) **O:** Supraspinatus fossa of scapula.  
**I:** Greater tubercle of humerus.
- (C) **O:** Spinous process of T-2 to T-5.  
**I:** Medial border of scapula between spine of the scapula and inferior angle.
- (D) **O:** External occipital protuberance, medial portion of superior nuchal line of occiput, ligamentum nuchae, and spinous processes of C-7 through T-12.  
**I:** Lateral one-third of clavicle, acromion, and spine of the scapula.
- (E) **O:** Lateral side of inferior angle and lower half of lateral border of scapula.  
**I:** Crest of the lesser tubercle of the humerus



# Posterior Origin and Insertion Exam



**(F) O:** Posterior iliac crest, iliolumbar ligament.

**I:** Last rib, transverse processes of the first through fourth lumbar vertebrae.

**(G) O:** Coccyx, posterior sacrum, posterior iliac crest, sacrotuberous and sacroiliac ligaments.

**I:** Gluteal tuberosity (upper fibers) and iliotibial tract (lower fibers).

**(H) O:** Anterior surface of sacrum.

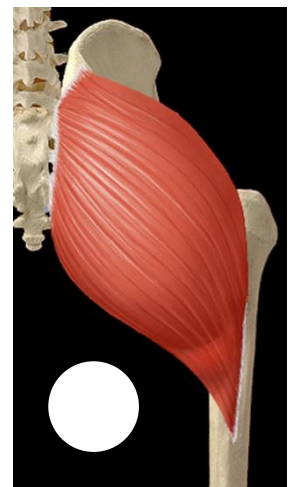
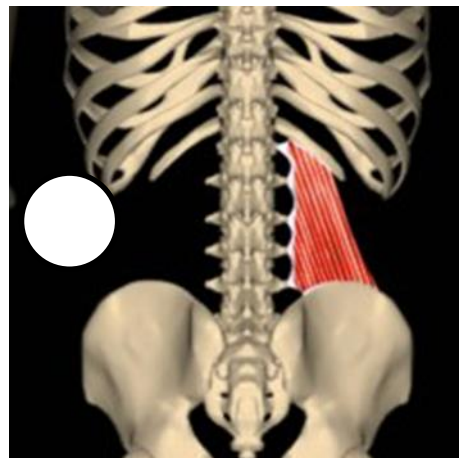
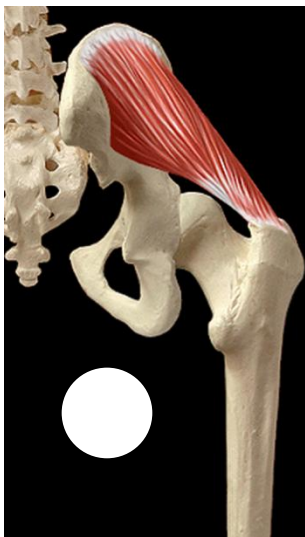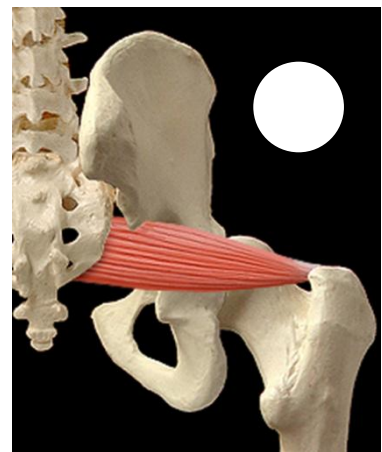
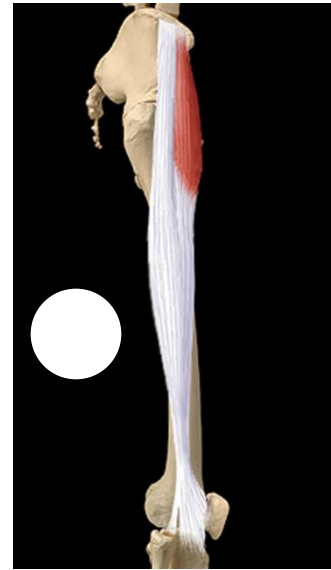
**I:** Greater trochanter.

**(I) O:** External surface the ilium between iliac crest and posterior and anterior gluteal lines.

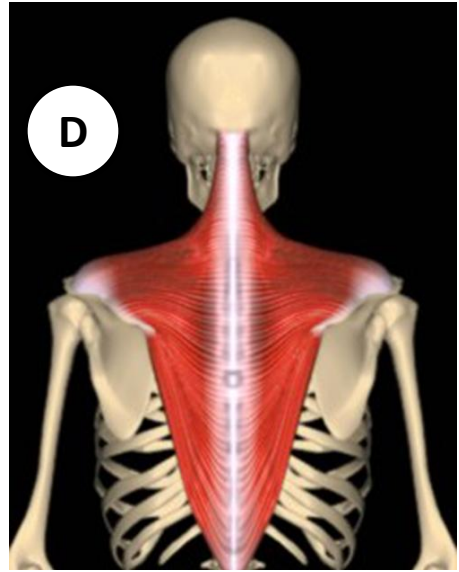
**I:** Greater trochanter.

**(J) O:** Iliac crest, posterior to the ASIS.

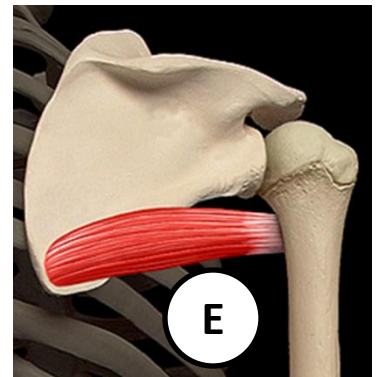
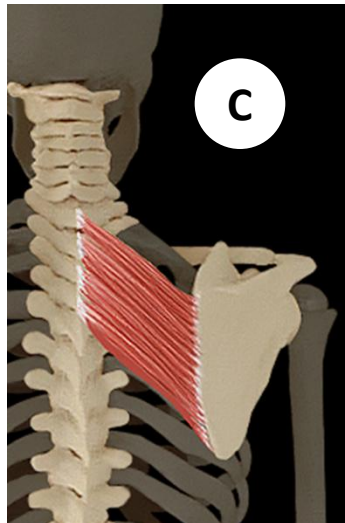
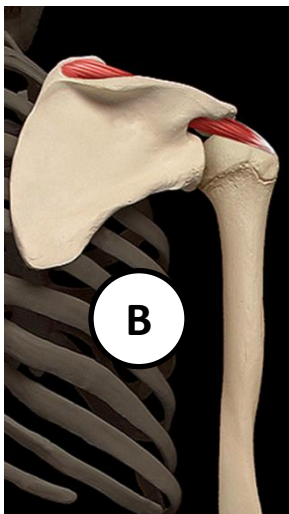
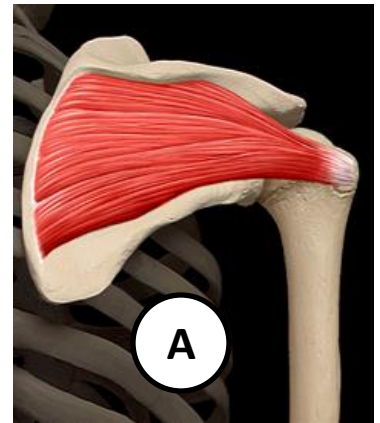
**I:** Iliotibial tract.



# Posterior Origin and Insertion Exam



- (A) **O:** Infraspinous fossa of scapula.  
**I:** Greater tubercle of humerus.
- (B) **O:** Supraspinatus fossa of scapula.  
**I:** Greater tubercle of humerus.
- (C) **O:** Spinous process of T-2 to T-5.  
**I:** Medial border of scapula between spine of the scapula and inferior angle.
- (D) **O:** External occipital protuberance, medial portion of superior nuchal line of occiput, ligamentum nuchae, and spinous processes of C-7 through T-12.  
**I:** Lateral one-third of clavicle, acromion, and spine of the scapula.
- (E) **O:** Lateral side of inferior angle and lower half of lateral border of scapula.  
**I:** Crest of the lesser tubercle of the humerus



# Posterior Origin and Insertion Exam



**(F) O:** Posterior iliac crest, iliolumbar ligament.

**I:** Last rib, transverse processes of the first through fourth lumbar vertebrae.

**(G) O:** Coccyx, posterior sacrum, posterior iliac crest, sacrotuberous and sacroiliac ligaments.

**I:** Gluteal tuberosity (upper fibers) and iliotibial tract (lower fibers).

**(H) O:** Anterior surface of sacrum.

**I:** Greater trochanter.

**(I) O:** External surface the ilium between iliac crest and posterior and anterior gluteal lines.

**I:** Greater trochanter.

**(J) O:** Iliac crest, posterior to the ASIS.

**I:** Iliotibial tract.

